VISION ACADEMY
people | research | education

VISION ACADEMY VIEWPOINT

The Vision Academy is a partnership between Bayer and ophthalmic specialists, established with the aim of addressing key clinical challenges in the field of retinal diseases

Suspending Treatment of Neovascular Age-Related Macular Degeneration in Cases of Futility

Background

Medical futility is the point at which a treatment is unlikely to provide any significant beneficial effect perceived by the patient. It may be quantitative, for example the inability to achieve further treatment goals, or qualitative, as in the inability to improve patient quality of life.[1,2]

Anti–vascular endothelial growth factor (anti-VEGF) therapy is the standard of care for patients with neovascular age-related macular degeneration (nAMD); however, factors including treating too late in the disease course, misdiagnosis, or coexistent disease may lead to poor treatment outcomes.[3–6]

In cases of medical futility (i.e. when the treatment cannot further improve patient outcomes or quality of life), there is a lack of guidance and consensus on the criteria for determining when treatment suspension should be considered.

A review of the literature and available evidence was conducted to:

- Identify criteria for determining benefits from anti-VEGF therapy as well as any additional factors that should be taken into consideration prior to suspension of treatment
- Develop a flow chart to help guide the management of patients with nAMD who do not perceive any benefits from anti-VEGF treatment

Developed on behalf of the Vision Academy Steering Committee in February 2020.

Date of review: September 2025

Full consensus Variations in opinion

Viewpoint

The Vision Academy has developed a treatment futility flow chart to determine whether anti-VEGF therapy should be continued in patients without perceived benefits from treatment.[7] The flow chart consists of five key stages: patient decision, treatment per protocol, treatment protocol adjustment, investigation of inadequate response, and establishment of anti-VEGF treatment futility. It is appropriate for patients meeting the following criteria:

- Unilateral or bilateral nAMD (the applicability of the flow chart is limited to the worse-seeing eye in bilateral disease; in cases of approximately equivalent visual acuity in both eyes, the flow chart should be limited to only one eye)
- No previous under- or overtreatment with an anti-VEGF
- No permanent damage to the macular center that is incompatible with visual improvement by anti-VEGF treatment
- Lesion size ⩽12 disc areas in greatest linear dimension

Stage 1: Patient decision

Patients consenting to intravitreal injections of anti-VEGF should receive treatment in accordance with the licensed protocol, with regular follow-up visits to assess nAMD disease activity, response to treatment, and to guide treatment protocol adjustment

- In cases where the patient does not wish to proceed with anti-VEGF therapy, their willingness to receive anti-VEGF treatment can be reassessed periodically at the discretion of the physician

Stage 2: Treatment per protocol

When evaluating response to anti-VEGF treatment in patients with nAMD, both functional changes (determined using visual acuity) and morphological changes (determined using a combination of imaging modalities, including OCT) should be considered, rather than visual acuity alone, in accordance with country-specific criteria for classifying response[6,8]

- Anti-VEGF treatment should be continued in accordance with the licensed posology in cases where there is improvement in lesion morphology despite a lack of functional response, or where there is an improvement in visual acuity without morphological response

Stage 3: Treatment protocol adjustment

In patients with poor response to anti-VEGF treatment after the initial loading phase of three monthly injections (as defined by country- and physician-specific criteria), the treatment protocol should be reassessed and, if necessary, adjusted to ensure maximal therapy

- If a response to anti-VEGF treatment is not improved with maximal therapy, the reason for inadequate response should be investigated

Vision Academy Viewpoints are intended to raise awareness of a clinical challenge within ophthalmology and provide an expert opinion to engage in further discussion.
The Vision Academy is sponsored by Bayer. This document was prepared on behalf of the Vision Academy by David T. Wong, Anat Loewenstein, Ian Pearce, and Annabelle A. Okada, and is endorsed by the Vision Academy Steering Committee.
Always refer to local treatment guidelines and relevant prescribing information.
The views represented in this document do not necessarily reflect those of Bayer.
September 2023 | MA-PFM-OPHT-ALL-0044-1

Figure. Algorithm for determining anti-VEGF treatment futility in patients with nAMD

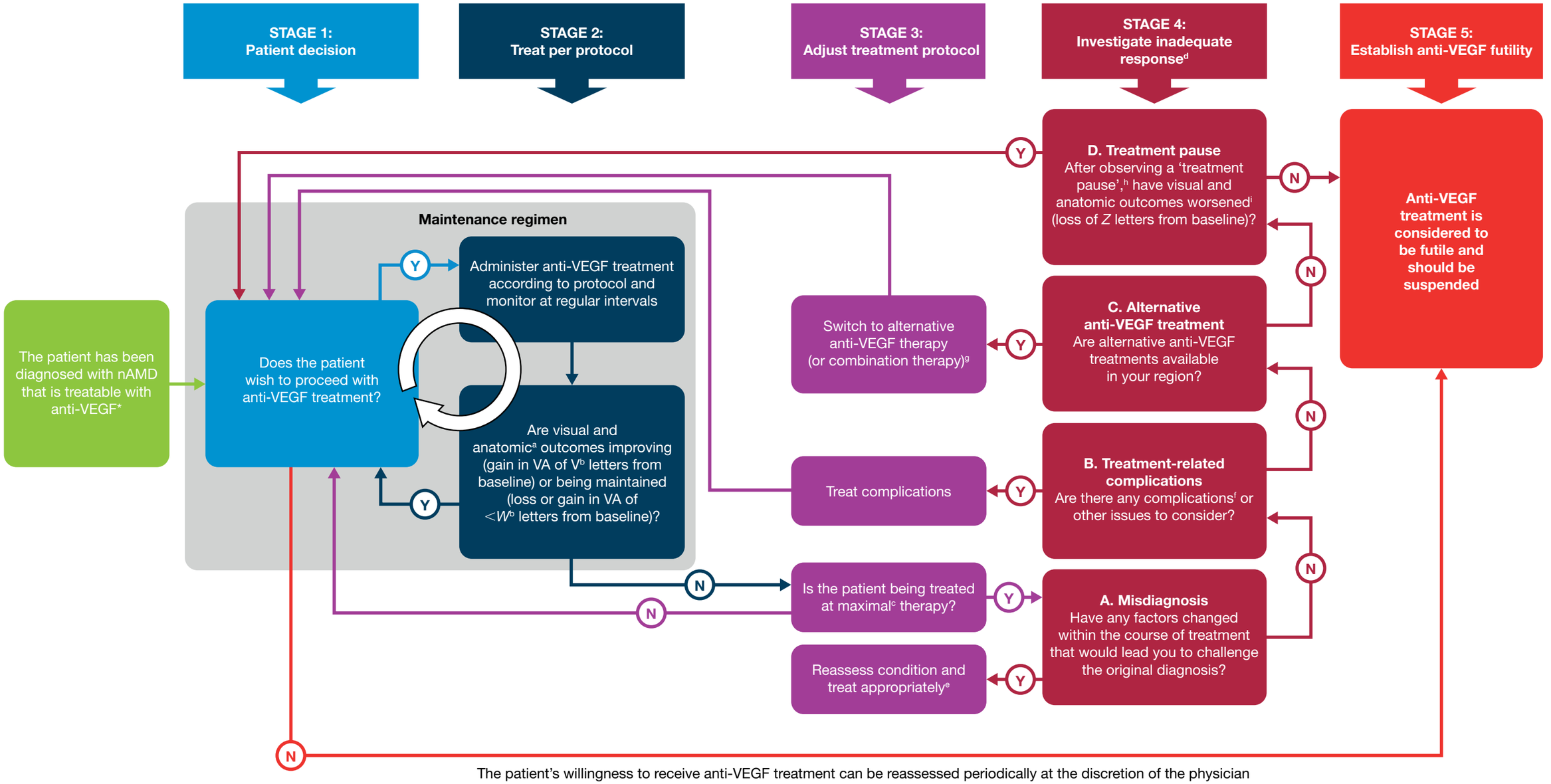

*All of the following apply to the eye in question: the patient has unilateral or bilateral nAMD (algorithm limited to the worse-seeing eye); anti-VEGF was administered in a correct and timely manner in previously treated patients; there is no permanent damage to the macular center that is incompatible with visual improvement by anti-VEGF treatment; lesion size is ⩽12 disc areas in greatest linear dimension; and there is evidence of disease progression as seen using fluorescein angiography or recent visual acuity changes. Within the algorithm, futility is defined as a state in which the recommendation is to suspend treatment, which is not limited to medical futility.

[a]OCT changes also to be considered here, in accordance with region- and physician-specific criteria.

[b]As defined by region-specific criteria.

[c]"Maximal therapy" is defined as the shortest dosing interval of 2–4 weeks (as defined by region- and physician-specific criteria).

[d]"Inadequate response" is defined as progressive deterioration in visual acuity of ⩾*X* letters from baseline in treated eye in primary phase (*X* defined by region-specific criteria).

[e]Alternative treatment options are available for subtypes of nAMD, such as polypoidal choroidal vasculopathy and retinal angiomatous proliferation.

[f]Complications may include thromboembolic events; anti-VEGF treatment should be suspended temporarily and then recommenced (period of time defined by region-specific criteria).

[g]When alternative anti-VEGF monotherapy is unavailable, the physician may consider combining with photodynamic therapy.

[h]"Treatment pause", or "treatment-free interval", is defined as *Y* weeks of no anti-VEGF treatment (period of time defined by region-specific criteria).

[i]"Worsening" is defined as loss of *Z* letters from baseline (*Z* defined by region-specific criteria).

References

1. Schneiderman LJ. Defining medical futility and improving medical care. *J Bioeth Inq* 2011; 8(2): 123–131.
2. Schneiderman LJ, Jecker NS and Jonsen AR. Medical futility: its meaning and ethical implications. *Ann Intern Med* 1990; 112(12): 949–954.
3. Waizel M, Todorova MG, Masyk M *et al.* Switch to aflibercept or ranibizumab after initial treatment with bevacizumab in eyes with neovascular AMD. *BMC Ophthalmol* 2017; 17(1): 79.
4. Waizel M, Rickmann A, Blanke BR *et al.* Response to bevacizumab after treatment with aflibercept in eyes with neovascular AMD. *Eur J Ophthalmol* 2016; 26(5): 469–472.
5. Broadhead GK, Hong T and Chang AA. Treating the untreatable patient: current options for the management of treatment-resistant neovascular age-related macular degeneration. *Acta Ophthalmol* 2014; 92(8): 713–723.
6. Amoaku WM, Chakravarthy U, Gale R *et al.* Defining response to anti-VEGF therapies in neovascular AMD. *Eye (Lond)* 2015; 29(6): 721–731.
7. Wong DT, Lambrou GN, Loewenstein A *et al.* Suspending treatment of neovascular age-related macular degeneration in cases of futility. *Retina* 2020; 40(6): 1010–1020.
8. The Royal College of Ophthalmologists. Age-related macular degeneration: guidelines for management. Available at: https://www.rcophth.ac.uk/wp-content/uploads/2014/12/2013-SCI-318-RCOphth-AMD-Guidelines-Sept-2013-FINAL-2.pdf. Accessed September 2019.
9. Vision Academy Steering Committee. Management of subfoveal hemorrhage. Available at: https://www.visionacademy.org/sites/g/files/dvfzvj331/files/2018-05/vision-academy-viewpoint-management-of-subfoveal-hemorrhage.pdf. Accessed December 2019.

Stage 4: Investigation of inadequate response to anti-VEGF treatment

Misdiagnosis

Where there is a lack of response after the initial 3-month anti-VEGF loading phase, the possibility of misdiagnosis should be considered and a reassessment of the condition and intervention should be carried out at the discretion of the physician and in accordance with region-specific factors

- Following insufficient initial response to anti-VEGF treatment and/or deterioration after the loading phase, multimodal imaging, including fluorescein angiography, ICGA, and OCT, should be utilized to reassess the condition

Treatment-related complications

Anti-VEGF therapy should be suspended temporarily at the discretion of the physician if treatment complications occur, until they are adequately resolved

- In less severe cases of subfoveal hemorrhage secondary to nAMD, anti-VEGF treatment should be continued before referring the patient for alternative treatments (e.g. tissue plasminogen activator, vitrectomy, and pneumatic displacement)[9]

Alternative anti-VEGF treatment

Patients with nAMD who have insufficient functional and morphological responses to anti-VEGF treatment should, where possible, receive an alternative anti-VEGF agent, in cases where potential confounding factors to treatment have been investigated and managed and diagnosis confirmed

- If an alternative anti-VEGF monotherapy is unavailable, combination treatment with photodynamic therapy should be considered

Treatment pause

To assess for treatment futility in cases of insufficient or no response to anti-VEGF treatment, a 1-month treatment pause followed by monthly monitoring visits (for up to 6 months) is an appropriate regimen

- If noticeable deterioration in visual or anatomical outcomes occurs during treatment pause, reinitiation of optimal anti-VEGF therapy is recommended

Stage 5: Establishment of anti-VEGF treatment futility

Anti-VEGF therapy should be suspended in patients with nAMD who are classed as non-responders. This includes patients for whom an insufficient response to treatment persists despite protocol adjustment, addressing complications/confounding factors, switching to alternative anti-VEGF agents, and implementation of a "treatment pause" (where appropriate)

- Continued monitoring at follow-up visits is recommended at the discretion of the physician

Further considerations

Overall, there remains a lack of substantive evidence on the management of patients with nAMD who are poor responders to anti-VEGF therapy. Further consideration to what constitutes treatment "success" with anti-VEGF therapy and the circumstances in which treatment suspension is appropriate may be warranted. Investigating the potential to reintroduce anti-VEGF treatment and development of an appropriate re-treatment protocol for patients for whom treatment was previously considered to be futile may be of benefit to the ophthalmic community.

Full consensus Variations in opinion

Vision Academy Viewpoints are intended to raise awareness of a clinical challenge within ophthalmology and provide an expert opinion to engage in further discussion.
The Vision Academy is sponsored by Bayer. This document was prepared on behalf of the Vision Academy by David T. Wong, Anat Loewenstein, Ian Pearce, and Annabelle A. Okada, and is endorsed by the Vision Academy Steering Committee.
Always refer to local treatment guidelines and relevant prescribing information.
The views represented in this document do not necessarily reflect those of Bayer.
September 2023 | MA-PFM-OPHT-ALL-0044-1

MA-PFM-OPHT-JP-0049-16-09